

A Patient with Renal AA Amyloidosis Following Pulmonary Squamous Cell Carcinoma: Case Report and Literature Review

Akciğer Skuamöz Hücreli Karsinoma Seyrinde Gelişen Böbrek AA Amiloidozis Olgusu: Olgu Sunumu ve Literatür Değerlendirme

ABSTRACT

A review of the literature reveals lung cancer associated AA amyloidosis in only 14 cases. With respect to histological subtype, eight of them were squamous cell carcinoma (SCC). Herein, we describe a patient with pulmonary squamous cell carcinoma (SCC)-associated AA amyloidosis. He presented with severe nephrotic syndrome three years after the diagnosis of malignancy and had no history of chronic inflammatory disease. Our reasons for evaluating these cases is that they are rare in the literature and most are SCC-associated AA amyloidosis.

KEY WORDS: AA amyloidosis, Lung cancer, Nephrotic syndrome, Squamous cell carcinoma

ÖZ

Literatür incelendiğinde 14 adet akciğer kanseri ilişkili olduğu düşünülen AA amiloidozis olgusuna rastlanmıştır. Histolojik alt tip olarak, kanser olgularının sekizi skuamöz hücreli karsinomdur (SCC). Burada, pulmoner skuamöz hücreli karsinom (SCC) ile ilişkili AA amiloidozlu bir hasta sunulmaktadır. Malignite tanısından üç yıl sonra şiddetli nefrotik sendrom ile seyreden olguda, kronik inflamatuvar hastalık öyküsü yoktur. Bu olguları değerlendirme nedenimiz; literatürde nadir görülmeleri ve çoğunun SCC ilişkili AA amiloidoz olmalarıdır.

ANAHTAR SÖZCÜKLER: AA amiloidoz, Akciğer kanseri, Nefrotik sendrom, Skuamöz hücreli karsinom

INTRODUCTION

Secondary amyloidosis (AA) is a disorder often associated with chronic inflammatory disease (i.e. Familial Mediterranean Fever-FMF). AA is caused by systemic extracellular accumulation of serum amyloid fibrils, primarily in the renal tissue (1,2). The association of amyloidosis AA with solid organ tumors is quite rare. It most commonly accompanies renal cell carcinoma (3). Amyloidosis AA has been described in a few patients with primary lung tumor (4-7). In the majority of these cases, histologic subtyping of the primary tumor has not been clearly elucidated but rather classified under 'Non-small cell lung carcinoma' (4,6).

Globally, lung cancer is the leading cause of death due to malignant diseases contributing to 17.6% of total cancer deaths (8). Today, it is notable that both the incidence of malignancy and/or cancer treatment-related renal diseases and the risk of cancer development in patients with nephrotic syndrome are increasing (9,10).

Indeed, the association between membranous glomerulonephritis (MGN) and cancer is not considered a coincidence but a classic paraneoplastic syndrome. Of the MGN, 10% are paraneoplastic, and lung cancer is the leading tumour type (9). Additionally, in a population-based cohort study in Denmark, patients with nephrotic syndrome demonstrated 73% increased risk of cancer (most often lung and kidney cancer) when compared to the general population (10).

Erhan TATAR¹
Funda TAŞLI²
Hasan ALPAY¹
Ali KORKMAZ³
Veli Kürşat CAYHAN⁴
Merve AKTAR¹
Nuran KATGI³
Murat KARATAŞ⁴
Adam USLU⁴

- 1 Health Sciences University, İzmir Bozyaka Education and Research Hospital, Department of Nephrology, İzmir, Turkey
- 2 Health Sciences University, İzmir Bozyaka Education and Research Hospital, Department of Pathology, İzmir, Turkey
- 3 Health Sciences University, Dr. Suat Seren Chest Diseases and Surgery Education Research Hospital, Department of Chest Diseases, İzmir, Turkey
- 4 Health Sciences University, İzmir Bozyaka Education and Research Hospital, Department of General Surgery, İzmir, Turkey

Received : 03.03.2018

Accepted : 06.04.2018

Correspondence Address:

Erhan TATAR
 Sağlık Bilimleri Üniversitesi,
 İzmir Bozyaka Eğitim ve Araştırma
 Hastanesi, Nefroloji Bilim Dalı,
 İzmir, Turkey
 Phone : +90 232 250 50 50
 E-mail : etatar@hotmail.com

The association of lung cancer with amyloidosis (AA) has been reported in only 14 cases. With respect to histological subtype, squamous cell carcinoma (SCC) constituted 8 of them. Herein, we report a case of severe nephrotic syndrome due to AA amyloidosis associated with SCC of the lung. In addition, we evaluate pulmonary SCC-induced amyloidosis AA cases in the literature.

CASE REPORT

A 67-year-old male patient presented to our outpatient clinic with extensive generalized edema, malnutrition and shortness of breath for 3 months. He was hospitalized upon detection of kidney failure accompanying severe nephrotic syndrome. Three years prior to admission, he was diagnosed with pulmonary squamous cell carcinoma (stage 3a- T2aN2M0) and treated non-surgically.

Transbronchial fine-needle aspiration cytology (FNAC) with sampling of mediastinal lymph nodes was used for the diagnosis of the primary pulmonary lesion and classifying the specific tumor type. The tumor had features of clustered polygonal cells with hyperchromatic nuclei, orangeophilic cytoplasm on Pap stain demonstrating keratinization, and a necrotic background. Immunohistochemistry staining to identify p63 and high-molecular weight cytokeratin positivity was not available.

At the time of cancer diagnosis, he received six cycles of cisplatin/ gemcitabine followed by radiotherapy. At the second year follow-up, metastasis to the opposite lung was detected on PET-CT and the patient received 4 cycles of carboplatin and docetaxel therapy. The last adjuvant chemotherapy had been administered 6 months ago. From cancer diagnosis to the last follow-up, the patient had no evidence of renal failure and hematuria or proteinuria. In addition, PET/CT examinations did not indicate any tumor or a lesion in the kidneys.

Laboratory data and blood chemistry included Albumin 1.5 g/dL, blood urea 31.0 mg/dL, creatinine 1.4 mg/dL, eGFR: 52 ml/min/1.72m², total cholesterol 456 mg/dL, triglyceride 571 mg/dL, quantitative proteinuria 11 gm/d, CRP 54.0 mg/dL (normal range: 0-5.0 mg/dL), and serum amyloid A (SAA) 34 mg/L (normal range: 0-6.4). Urinalysis revealed 3+ proteinuria and no hematuria.

The patient underwent renal biopsy. Immunofluorescence microscopy showed no specific features. On H&E-stained tissue sections, there was eosinophilic material in 21 glomeruli, arterioles and interstitium, which were also weakly stained with PAS. The Congo red study demonstrated capillary wall staining with global and segmental staining of amorphous deposits in 3 and 18 glomeruli, respectively. In addition, immunohistochemistry (IHC) detected serum amyloid A related (AA) amyloid in the specimen (Figure 1).

The FMF gene mutation analysis of the patient was negative and no monoclonal gammopathy was detected in protein and immunofixation electrophoresis

The patient had no history of chronic inflammatory arthritis, chronic sepsis, tuberculosis, periodic fever syndromes (FMF) or Crohn's disease. Thus, the AA type amyloidosis was associated with squamous cell carcinoma of the lung. The patient had ECOG Performance Status III which impeded any further treatment and he was discharged with the maintenance of best supportive care.

DISCUSSION

The association of primary lung tumors and amyloidosis AA is extremely rare in the literature and the number of cases reported to date is fourteen. Of these, 9 cases are classified as non-small cell lung cancer. However, the pathological subtyping of this group disclosed SCC histology in eight of them (8/9). In particular, the association of AA with SCC of the lung is noteworthy but it is not yet certain whether it is a coincidence or a pathogenetic mechanism by which we can derive a causal relationship. In order to specify the frequency of AA deposition in SCC, Ueno et.al. examined 266 specimens of SCC or dysplasia in the oral cavity, pharynx and larynx and identified amyloid deposition in 11%, 36.4% and 59.5% in the squamous cell lesions of the oral cavity, pharynx and larynx, respectively. These findings highlight the increased predisposition of amyloid accumulation particularly in SCC of the distal portions of the upper respiratory tract (11). In this study, the association of AA amyloidosis with all SCCs was 29% and AA overexpression was found to be higher in SCC cases compared to dysplasia (40% vs. 59.5%; respectively). Among the anticytokeratin monoclonal antibodies, CK1 and CK14 reacted with 100% and 44.4% of the amyloid deposits of squamous cell carcinomas suggesting that SCC-associated AA may originate from cytokeratins in cancer cells. Similarly, 4 of the 8 cases (SCC of the lung with AA) mentioned above had AA overexpression in lung tissue, and 3 of them had a lethal course and were described in the necropsy study.

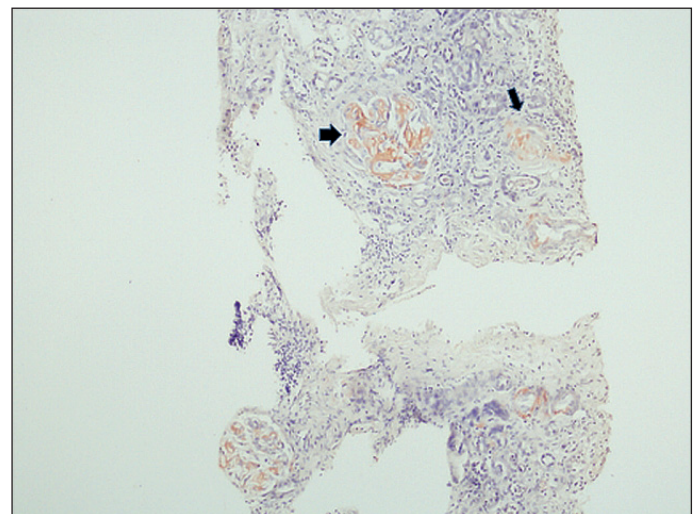


Figure 1: Amyloid deposition in glomeruli and vessels (Congo Red; x100).

Table I: Biopsy-proven AA amyloidosis associated with squamous cell carcinoma of the lung.

No	Author, (year)	Age (year)/sex	Diagnostic method/involved organ(s)	Local/Generalized Disease AA overexpression	Time to detection of AA following cancer diagnosis	Outcome
1	Kimball et al (1961)	?	Autopsy series/necropsy	Generalized AA	unknown	died
2	Melato et al (1981)	?	Autopsy series/necropsy (lung)	Local AA	unknown	died
3	Meyrier A et al (1985)	59/M	Case report/kidney biopsy	Generalized AA	One year ago	died
4	Focan et al (1985)	70/M	Case report/necropsy (gastrointestinal tract and bone marrow)	Generalized AA	unknown	died
5	Richmond et al (1990)	72/M	Case report/necropsy (Lung, kidney, bowel, adrenal glands, liver, spleen, portal vein and pancreatic vessels).	Local and Generalized AA	Simultaneously	died
6	Garthwaite et al (2003)	64/M	Case report/lung and kidney biopsy	Local and Generalized AA	unknown	alive
7	Barceló et al (2003)	33/M	Case report/rectal biopsy	Generalized AA	20 days	died
8	Gueutin et al (2013)	56/M	Case report/kidney biopsy	Generalized AA	One year ago	alive
9	Our case	67/M	Case report/kidney biopsy	Generalized AA	Three years ago	alive

In another study, Oz et al. investigated the clinicopathological behaviour of amyloidosis A (AA) in renal cell carcinoma (RCC) patients and reported overexpression of AA in high-grade tumors. These RCC cases with increased immunoexpression of AA had very poor survival (12). In the light of this information, association of pulmonary SCC with AA overexpression may be a poor prognostic indicator. There is a need for large-scale work in this area.

Including our patient, three cases in the literature have presented with AA amyloidosis months or years after the diagnosis of malignancy (5,7). Almost all had systemic organ involvement, mainly the kidney. In some cases, the presence of AA in the pulmonary tissue has suggested that SCC-induced Serum Amyloid A may be responsible for the process (13). Serum amyloid A is an inflammation-induced acute phase reactant released by cytokines. Serum AA levels have been associated with the clinical stage and progression of various cancers such as hepatocellular carcinoma, and ovarian, renal, uterine, nasopharyngeal and lung cancer (13). In the meta-analyses of Biaoxue R et al. (9 trials, 1392 cases) for lung cancer, SAA levels were shown to be higher than in healthy individuals and associated with disease progression (14). Furthermore, when lung cancer subtypes are evaluated, the SAA increase in SCC is significantly higher than in the other carcinomas. In conclusion, SAA may have both diagnostic and prognostic value in SCC of the lung and may be an important factor leading to the development of AA type amyloidosis in these cases.

The characteristics of our patient and other cases in the literature are depicted in Table I.

In conclusion, AA type amyloidosis is more common in SCC type lung cancer. At the time of SCC diagnosis, local AA overexpression in lung biopsy is a poor prognostic indicator. SCC-associated high SAA levels may be responsible for AA type amyloidosis with systemic organ involvement and these patients often present with nephrotic syndrome. Further work is needed to clarify this issue.

REFERENCES

1. Lachmann HJ, Goodman HJ, Gilbertson JA, Gallimore JR, Sabin CA, Gillmore JD, Hawkins PN: Natural history and outcome in systemic AA amyloidosis. *New Engl J Med* 2007;356:2361-2371
2. Sarı İ, Birlik M, Kasifoğlu T: Familial Mediterranean fever: An updated review. *Eur J Rheum* 2014;1:21-33
3. Vanatta PR, Silva FG, Taylor WE, Costa JC: Renal cell carcinoma and systemic amyloidosis: Demonstration of AA protein and review of the literature. *Human Pathology* 1983;14:195-202
4. Barcelo JR, Munoz A, Mane JM, Rubio I, Hoyos TP, Viteri A, Lopez-Vivanco GM: Amyloidosis and lung cancer. *Clin Lung Cancer* 2003;4:249-251
5. Meyrier A, Makdassi R, Breau JL, Amouroux J, Mougnot B: AA amyloidosis and the nephrotic syndrome complicating a pulmonary epidermoid carcinoma. *Nephrologie* 1985;6:191-192

6. Paydas S, Soydas B, Paydas S, Balal M, Erdogan S, Tuncer I: Different glomerulopathies accompanying non-small-cell lung cancer. *Mt Sinai J Med* 2005;72:279-281
7. Gueutin V, Langlois AL, Shehwaro N, Elharraqui R, Rouvier P, Izzedine H: Nephrotic Syndrome associated with lung cancer: A rare case of malignancy associated with AA amyloidosis. *Case Rep Nephrol* 2013;2013:831903
8. Jemal A, Bray F, Center MM, Ferlay J, Ward E, Forman D: Global cancer statistics. *CA Cancer J Clin* 2011;61:69-90
9. Mora-Mora MT, Rangel-Hidalgo G, Gallego-Domínguez MS, Cebrián-Andrada CJ, González-Sanchidrián S, Labrador-Gómez PJ, García-Bernalt V, Marín-Álvarez JP, Castellano I, Novillo-Santana R, Deira J, Gómez-Martino Arroyo JR: Membranous glomerulonephritis secondary to neoplasia. Different forms of presentation. *Nefrologia* 2012;32:547-548
10. Christiansen CF, Onega T, Sværke C, Körmendiné Farkas D, Jespersen B, Baron JA, Sørensen HT: Risk and prognosis of cancer in patients with nephrotic syndrome. *Am J Med* 2014;127:871-877
11. Ueno T, Hoshii Y, Cui D, Kawano H, Gondo T, Takahashi M, Ishihara T: Immunohistochemical study of cytokeratins in amyloid deposits associated with squamous cell carcinoma and dysplasia in the oral cavity, pharynx and larynx. *Pathol Int* 2003;53:265-269
12. Oz Atalay F, Aytac Vuruskan B, Vuruskan H: Significance of amyloid A immunorexpression in the prognosis of renal cell carcinoma. *APMIS* 2016;124:257-262
13. Moshkovskii SA: Why do cancer cells produce serum amyloid A acute-phase protein? *Biochemistry (Mosc)* 2012;77:339-341
14. Biaoxue R, Hua L, Wenlong G, Shuanying Y: Increased serum amyloid A as potential diagnostic marker for lung cancer: A meta-analysis based on nine studies. *BMC Cancer* 2016;16:836