

# Shiga Toxin-Associated Hemolytic Uremic Syndrome and Unexpected Course

## *Shiga Toksin İlişkili Hemolitik Üremik Sendrom Tanılı Bir Olguda Beklenmedik Klinik Seyir*

### ABSTRACT

Hemolytic uremic syndrome is a disease that often requires the transfusion of blood products. A child (two and a half years old, boy) with Shiga toxin-associated hemolytic uremic syndrome who developed respiratory distress after transfusion is presented. The patient was diagnosed with Transfusion-Related Acute Lung Injury (TRALI) after eliminating other possibilities. Transfusions may be complicated by a low rate of potential fatal transfusion-related reactions like TRALI.

**KEY WORDS:** STEC-HUS, Transfusion, TRALI

### ÖZ

Hemolitik Üremik Sendrom sık transfüzyon ihtiyacı gerektiren bir hastalıktır. Shiga toksin ilişkili Hemolitik Üremik Sendrom tanısı alan iki buçuk yaşında bir erkek olguda transfüzyon sonrası solunum sıkıntısı gelişmiştir. Olgu bütün olasılıklar değerlendirildikten sonra Transfüzyon İlişkili Akut Akciğer Hasarı (TRALI) tanısı almıştır.

**ANAHTAR SÖZCÜKLER:** STEC-HUS, Transfüzyon, TRALI

### INTRODUCTION

Shiga toxin-associated hemolytic uremic syndrome (STEC-HUS), a thrombotic microangiopathy, is the most common cause of pediatric acute kidney injury but has no direct treatment (1). Most patients will be treated symptomatically with careful fluid and electrolyte management, nutritional support, and medication for hypertension. More severely affected patients require renal replacement therapy and may need intensive care (2). Hemolytic uremic syndrome is a disease that often requires the transfusion of blood products. Thrombocytopenia and anemia are common problems in this disorder and may need transfusion within certain indications. Although fresh frozen plasma infusions and plasma exchange are suggested, this is controversial in STEC-HUS treatment (3). Transfusion medicine is a common practice in the emergency department and other outpatient settings in the childhood period, and may be

complicated by fatal transfusion-related reactions. One of them is Transfusion-related acute lung injury (TRALI) that is the most common cause of transfusion-related death world-wide. This article presents a case of TRALI that was diagnosed and treated.

### CASE REPORT

A male patient aged two and a half years presented at the emergency department with vomiting and diarrhea for two days. Physical examination revealed weight 15 kg (> 95 p), height 60 cm (> 90 p), and BP 106/69 mm Hg (<90 p). The patient had a pale skin color and facial petechial rash. Mild bifissure edema was present. Laboratory tests revealed Hb 8.4 g/dl, WBC 10.000/mm<sup>3</sup>, Plt 53.000/mm<sup>3</sup>, BUN: 41 mg/dL, creatinine 2.6 mg/dl, K 4 mEq/L, Na 134 mEq/L, Ca 8.3 mg/dL, Uric Acid 8.6 mg/dL, albumin 3.4 g/dl, AST 223 U/L, ALT 155 U/L, LDH 412 IU/L, Amylase 70 U/L, and C3 105 mg/dL. Helmet cells, acanthocytes

**Hakan ERDOĞAN<sup>1</sup>**  
**Gökçe Nur AŞKIN<sup>1</sup>**  
**Şenay MENGİ<sup>2</sup>**  
**Nevin KILIÇ<sup>2</sup>**  
**Mehmet Fatih ORHAN<sup>3</sup>**

- 1 Bursa Yüksek İhtisas Training and Research Hospital, Department of Pediatric Nephrology, Bursa, Turkey
- 2 Bursa Yüksek İhtisas Training and Research Hospital, Department of Pediatric Intensive Care, Bursa, Turkey
- 3 Bursa Yüksek İhtisas Training and Research Hospital, Department of Pediatric Hematology, Bursa, Turkey



Received : 20.01.2017

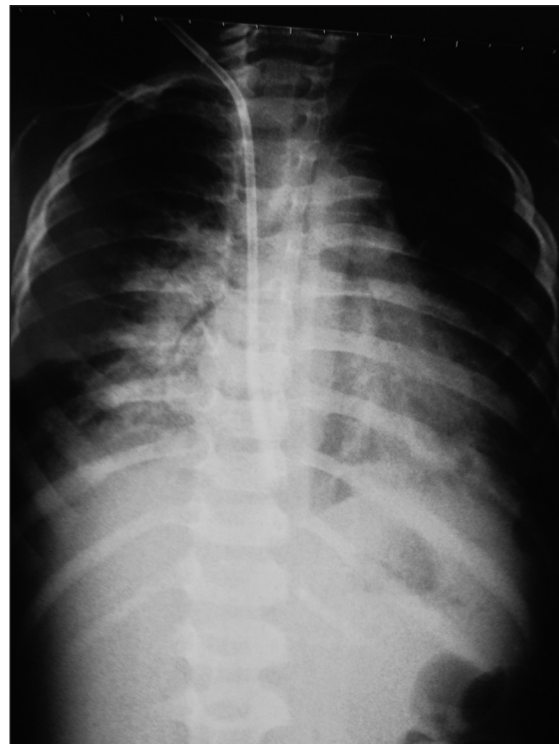
Accepted : 05.04.2017

Correspondence Address:

**Hakan ERDOĞAN**  
 Bursa Yüksek İhtisas Eğitim ve Araştırma Hastanesi, Çocuk Nefroloji Bölümü,  
 Bursa, Turkey  
 Phone : +90 224 451 10 09  
 E-mail : drerdoganha@yahoo.com

and rare schistocytes were seen with the peripheral blood smear. The reticulocyte count was 3.4%. On urine examination, the density was 1007, Proteins (++) and urine microscopy showed 4-5 leukocytes and 15-20 erythrocytes in each field. Arterial blood gases were pH 7.33, pCO<sub>2</sub> 26 mm Hg, PO<sub>2</sub> 60 mm Hg, BE:-10, and HCO<sub>3</sub> 15. Abdomen ultrasonography revealed no pathologic findings except grade 2-3 increased echogenicity in both kidneys. The patient was considered to be suffering from shiga toxin-associated hemolytic uremic syndrome with these clinical and laboratory findings. Diarrhea was not observed at follow up and a bacteriological diagnosis could not be made. ADAMTS13 was found within the normal ranges in terms of TTP. Since the patient had overload symptoms and urine output was low since hospitalization, fluid therapy was set up as insensible fluid loss + urine output. Furosemide treatment was started at 2 mg/kg/day in 2 doses. The first 2 days, two doses of fresh frozen plasma (FFP) were administered by infusion. At the first day of hospitalization, a Hb level of 5.2 g/dl and Plt value of 53.000/mm<sup>3</sup> were detected and one unit of erythrocyte suspension was given. Despite the furosemide therapy, the urine output was 0.3 ml/kg/hour and BUN 62 mg/dl, Creatinine 4.06 mg/dl, and K 3.9 mEq/L were found. Because of the pronounced overload symptoms, a jugular catheter was inserted after 1 unit platelet transfusion. The patient underwent hemodialysis for 7 times during 14 days of follow-up. Due to hypertension during follow-up, amlodipine was added to the treatment. On the 5th day of follow-up, the Hb value was 5.9 g/dl and erythrocyte suspension was transfused. An increase in the platelet count and urine output was observed after the 5th day. On the 17th day of hospitalization; when the patient had no treatment, normal urine output, decreased edema, normal blood pressure and gradually improved renal functions were observed. Despite the normal platelet count, the Hb level was 5.9 g/dl. The patient still needed to be monitored at the intensive care unit. The laboratory findings of hemolysis still continued slightly (such as reticulocytosis, high LDH levels) and an erythrocyte suspension was therefore planned for the third time. Respiratory distress and hypertension developed during the transfusion. The patient had tachypnea with a respiratory rate of 70/min and no pathologic finding at auscultation. Blood pressure was 105/72 mm Hg (<90 p), SpO<sub>2</sub> was 85 mm Hg. Arterial blood gas values were pH 7.35, pO<sub>2</sub> 30 mm Hg, HCO<sub>3</sub> 24, pCO<sub>2</sub> 44 mm Hg, and BE -2. The transfusion was terminated. Considering possible transfusion reactions, antihistamines and steroids were administered but no decrease in clinical signs were observed. Considering the possibility of transfusion-related increase in preload because of the release rate, 1 mg/kg furosemide was administered but no response was observed. Deleted cardiac shadow and paracardiac infiltration were detected on the chest radiograph (Figure 1). Tachypnea starting suddenly during transfusions is the most remarkable clinical finding of patients diagnosed shiga toxin-associated hemolytic uremic syndrome (STEC-HUS). Antihistamines and steroids were administered considering the possibility of

a transfusion reaction and anaphylaxis because of the sudden onset of clinical findings but there was no response. Despite the good urine output, normal blood pressure and lack of edema on physical examination, furosemide was administered considering the possibility of pulmonary edema but did not result in any change in the clinical signs. Echocardiography performed during this period showed no evidence of volume overload. The chest x-ray suggested the possibility of pneumonia but the patient had normal auscultation findings, no fever, and normal leukocyte count and CRP value. There was no positive blood culture or clinical signs of pneumonia. After the tenth day of hospitalization, the patient's platelet counts returned to normal and thrombocytopenia was not at a level that would cause spontaneous alveolar hemorrhage. In this period with tachypnea and low SpO<sub>2</sub>, the most important laboratory finding was low arterial pO<sub>2</sub>. After eliminating other possibilities, transfusion-related acute lung injury (TRALI) was considered with the clinical picture developing during the transfusion, the chest x-ray image, and low arterial pO<sub>2</sub>. Transfusion was stopped when tachypnea started and O<sub>2</sub> support was initiated. Preparation for mechanical ventilation was made and O<sub>2</sub> support continued while feeding was discontinued. The patient was treated with 2 mg/kg/day intravenous methylprednisolone in 2 doses for 2 days. SpO<sub>2</sub> and pO<sub>2</sub> increased gradually, CO<sub>2</sub> retention did not develop and there was no need for mechanical ventilation. At the end of the second day, the patient's respiratory distress and chest x-ray improved (Figure 2). The patient's laboratory test results at referral and on the 7th and 17th days are listed in Table I.



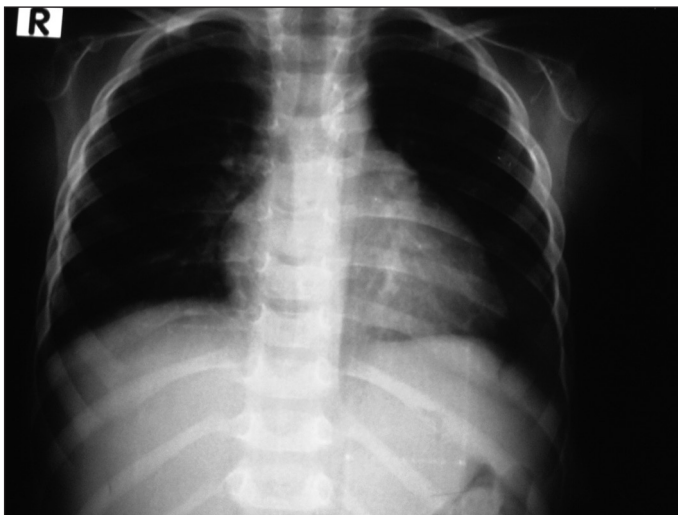**Figure 1:** X-Ray after transfusion.

**Table I:** Patient laboratory results.

	Day 0	Day 7	Day 17
BUN (mg/dl)	41	58	22
Creatinine (mg/dl)	2.60	4.4	0.65
Uric acid (mg/dl)	8.6	3.92	4.4
AST (U/L)	223	31	26
ALT (U/L)	155	15	7
LDH (IU/L)	412	367	312
Calcium (mg/dl)	8.33	9.5	9.3
Sodium (mmol/L)	134	132	138
Potassium (mmol/L)	4	3.97	4.5
Albumin (gr/dl)	3.4	4.5	4.4
CRP (mg/L)	20.7	34	3.1
WBC (/mm <sup>3</sup> )	10.000	6.600	8.500
Hb (gr/dl)	8.4	7.5	5.9
Plt (/mm <sup>3</sup> )	53.000	28.000	220.000
Reticulocyte (%)	3.4	2.8	5
Haptoglobin (mg/dl)		223	

**Table II:** Definition of transfusion-related acute lung injury (TRALI).

<p><b>Suspected TRALI</b></p> <ul style="list-style-type: none"> <li>• Acute onset within 6 h of blood transfusion</li> <li>• PaO<sub>2</sub>/FIO<sub>2</sub>&lt;300 mm Hg, or worsening of P to F ratio</li> <li>• Bilateral infiltrative changes on chest radiograph</li> <li>• No sign of hydrostatic pulmonary oedema (pulmonary arterial occlusion pressure</li> <li>• ≤18 mm Hg or central venous pressure ≤15 mm Hg</li> <li>• No other risk factor for acute lung injury</li> </ul>
<p><b>Possible TRALI</b></p> <ul style="list-style-type: none"> <li>• Same as for suspected TRALI, but another risk factor present for acute lung injury</li> </ul>
<p><b>Delayed TRALI</b></p> <ul style="list-style-type: none"> <li>• Same as for (possible) TRALI and onset within 6-72 h of blood transfusion</li> </ul>



**Figure 2:** X-Ray after treatment.

## DISCUSSION

Transfusion-related acute lung injury (TRALI) can develop due to the administration of plasma and plasma-rich products, but is a rare complication of transfusion. It is one of the most important causes of mortality and morbidity in transfusion (4). In the United States, the incidence of TRALI before 2007

was estimated as 1 in 4000-5000 transfusion units but in 2009, with the help of preventive measures, the incidence was estimated as 1 in 12.000 (5). Despite the low overall incidence, it is associated with a significant overall mortality of 5-10%, and is the leading cause (approximately 50%) of transfusion-associated death in the US (6). An attempt has been made to explain the development of the TRALI syndrome by two different mechanisms. Anti-leukocyte antibodies from blood products mediating leucoagglutination (immune mechanisms) or the activation of neutrophils due to bioactive lipids in blood products (non-immune mechanism) are thought to be related with the development of TRALI. The common point of these mechanisms, lung damage by neutrophils, plays a role in the early immune response. Although all blood products carry risk, the condition is seen most commonly with plasma transfusions (7). Dyspnea, tachypnea, tachycardia, cyanosis, hypotension and fever are the most common clinical signs and symptoms. The first step of the diagnosis is to rule out pulmonary edema. In 2004, diagnostic criteria were determined for determining TRALI due to transfusion-dependent overload or similar causes (Table II) (8). Before diagnosing TRALI according to the diagnostic criteria, it is necessary to exclude volume overload, transfusion of acute hemolytic transfusion reaction, anaphylactic transfusion reactions, and other causes of ARDS. There is no specific treatment for TRALI like other forms of ARDS. TRALI is self-limited disorder and therefore has a better prognosis than other forms of ARDS. Some other factors that can influence TRALI's prognosis are early diagnosis and early supportive treatment (5). Immediate cessation of transfusion, appropriate fluid and electrolyte support, and oxygen and ventilatory support to protect the patient from hypoxemia constitute essential treatment. Although some case reports have mentioned the benefits of glucocorticoid therapy, there is no controlled prospective clinical study yet (5). Donor related precautions against TRALI are washing, plasma reduction, leucofiltration,

S/D plasma use and the donor choosing precautions are male donor preference, HLA, HNA and antibody screening systems. In our case, tachypnea developed 2 hours after the transfusion and bilateral paracardiac infiltration was seen in the lung graph, although there was no prior lung disease. No clinical or laboratory sign of volume overload was spotted before and during the transfusion. No response to appropriate doses of antihistamines, anti-inflammatory and diuretic therapy, together with the absence of additional evidence other than respiratory distress, ruled out the acute hemolytic transfusion reactions and acute pulmonary edema. After transfusion, cross-match incompatibility was not found on repeated tests. The respiratory distress of the patient, who had received supplemental oxygen treatment, decreased at 48 hours. It is reported that hypotension is noted among the clinical signs, and some patients may be hypertensive. The patient's blood pressure increased from time to time and the captopril therapy previously started was continued. Avoiding diuretic treatment in TRALI is recommended in the literature. We also did not use diuretic treatment after initially ruling out the possibility of volume overload. Keeping the risk of hypertension and hyperkalemia in mind, erythrocyte transfusions should be administered before the levels of Hb 6-7 gr/dl in HUS, especially in oligo-anuric patients who do not have heart failure signs. Platelet infusions are contra-indicated unless a severe hemorrhagic condition is present or a surgical procedure is planned. Using plasma infusions for conditions other than these can cause more damage in the blood vessels and worsen the thrombotic microangiopathy (3). In our center, FFP support is provided for 1-2 days until the diagnosis of STEC-HUS is certain. When there is no clinical benefit, the plasma infusions are stopped. It has long been known that repeated administration of blood products increases the risk of TRALI (9). After this complication that we encountered for the first time, we will reconsider plasma infusions in patients with STEC-HUS.

In conclusion, Hemolytic uremic syndrome, is a disease that often requires the transfusion of blood products, and the risk of developing TRALI should be considered during these transfusions.

## REFERENCES

1. Keir LS: Shiga toxin associated hemolytic uremic syndrome. *Hematol Oncol Clin North Am* 2015;29:525-539
2. Trachtman H: HUS and TTP in children. *Pediatr Clin North Am* 2013;60:1513-1526
3. Salvadori M, Bertoni E: Update on hemolytic uremic syndrome: Diagnostic and therapeutic recommendations. *World J Nephrol* 2013;2:56-76
4. Álvarez P, Carrasco R, Romero-Dapueto C, Castillo RL: Transfusion Related Acute Lung Injured (TRALI): Current Concepts. *Open Respir Med J* 2015;9:92-96
5. Sayah DM, Looney MR, Toy P: Transfusion reactions newer concepts on the pathophysiology, incidence, treatment and prevention of Transfusion-Related Acute Lung Injury. *Crit Care Clin* 2012;28:363-372
6. Sokolovic M, Pastores SM: Transfusion therapy and acute lung injury. *Expert Rev Respir Med* 2010; 4:387-393
7. Sachs UJ: Pathophysiology of TRALI: Current concepts. *Intensive Care Med* 2007;33 Suppl 1:S3-S11
8. Vlaar AP, Juffermans NP: Transfusion-related acute lung injury: A clinical review. *Lancet* 2013; 382:984-994
9. Fowler AA, Hamman RF, Good JT, Benson KN, Baird M, Eberle DJ, Petty TL: Adult respiratory distress syndrome: Risk with common predispositions. *Ann Intern Med* 1983;98:593-597